

## Effects of ZooBioR2 product as feed supplement in laying hens on the morphofunctional state of intestinal mucosa

[Efeitos do produto ZooBioR2 como suplemento alimentar em galinhas poedeiras sobre o estado funcional da mucosa intestinal]

A. Bondar<sup>1</sup>, V. Macari<sup>2</sup>, V. Rudic<sup>3</sup>, G. Pistol<sup>2</sup>, V. Putin<sup>2</sup>, A. Rotaru<sup>2</sup>,  
T. Chiriac<sup>3</sup>, G. Solcan<sup>1\*</sup>, C. Solcan<sup>1</sup>

<sup>1</sup>University of Life Sciences, Ion Ionescu de la Brad from Iași, Romania  
Faculty of Veterinary Medicine

<sup>2</sup>State Agrarian University from Moldova, Faculty of Veterinary Medicine, Chișinău, Moldova

<sup>3</sup>Sciences Academy from Moldova, Institute of Microbiology and Biotechnology, Chișinău, Moldova

### ABSTRACT

*Spirulina platensis* is a microalga with biological activity used to produce nutritional supplements rich in proteins, essential fatty acids, vitamins, and minerals. The current study aims to prove the impact of the product ZooBioR2 (obtained from *Spirulina platensis*) on health, and on the histology of duodenum, jejunum, ileum, and cecum in laying hens. The experiment was performed in duplicate on 5 groups of hens (14 birds/group), one control and four experimental, in which the feed was supplemented with ZooBioR2 in different doses (5.0; 10.0; 15.0; 20.0mg active substance/kg of fodder). Inclusion of the supplement in the diet have determined a significant decrease of height of intestinal villi, the depth of the crypts and the thickness of muscular layer of mucosa in the experimental groups receiving 15.0 and 20.0mg/kg. The decrease of crypts depth is an indicator of a higher rate of turn-over of epithelial tissue. The morphological changes of intestinal mucosa could be involved in a better digestibility of the fodder.

Keywords: *Spirulina platensis*, growth promoters, laying hens, intestine, histology

### RESUMO

*Spirulina platensis* é uma microalga com atividade biológica utilizada para produzir suplementos nutricionais ricos em proteínas, ácidos graxos essenciais, vitaminas e minerais. O estudo atual visa provar o impacto do produto ZooBioR2 (obtido da *Spirulina platensis*) na saúde e na histologia do duodeno, jejuno, íleo e ceco em galinhas poedeiras. O experimento foi realizado em duplicata em cinco grupos de galinhas (14 aves/grupo), um controle e quatro experimentais, nos quais a ração foi suplementada com ZooBioR2 em diferentes doses (5,0; 10,0; 15,0; 20,0mg de substância ativa/kg de forragem). A inclusão do suplemento na ração determinou uma diminuição significativa da altura das vilosidades intestinais, da profundidade dos crypts e da espessura da camada muscular da mucosa nos grupos experimentais que receberam 15,0 e 20,0mg/kg. A diminuição da profundidade das criptas é um indicador de maior taxa de rotação do tecido epitelial. As alterações morfológicas da mucosa intestinal podem estar envolvidas em uma melhor digestibilidade da forragem.

Palavras-chave: *Spirulina platensis*, promotores de crescimento, galinhas poedeiras, intestino, histologia

### INTRODUCTION

Non-antibiotic growth promoters (NGPs) include acidifiers, probiotics, prebiotics, phytobiotics, feed enzymes, immune stimulants, and antioxidants that have recently gained attention.

(Dragland *et al.*, 2003). They have several important bioactive components, such as alkaloids, bitters, flavonoids, glycosides, mucilages, saponins, tannins phenols, phenolic acids, quinones, coumarins, terpenoids, essential oils, lectins, and polypeptides (Cowan, 1999) in

\*Corresponding author: gsolcan@uaiasi.ro

Submitted: October 26, 2021. Accepted: November 25, 2021.

the structures of most plants. *Spirulina platensis* is a cyanobacterium that is generally considered a rich source of protein, essential fatty acids, vitamins, and minerals. Spirulina has traditionally been used as a nutrient for humans for hundreds of years. Spirulina is also known to be rich in thiamine, riboflavin, pyridoxine, vitamin B 12, vitamin C, gamma linoleic acid, phycocyanins, tocopherols, chlorophyll,  $\beta$ -carotene, and carotenoids (Khan *et al.*, 2005). Until recently, the interest in Spirulina was mainly for its nutritional value. However, in recent years it has been found that there are many additional pharmacological properties. Many preclinical and clinical studies suggest several therapeutic effects ranging from lowering cholesterol and tumors to improving the immune system, an increase in intestinal lactobacilli, reducing nephrotoxicity through exposure to heavy metals, drugs, and radiation protection (Blinkova *et al.*, 2001; Kuhad *et al.*, 2006). Spirulina is also well known to have antioxidant properties, which are attributed to molecules such as phycocyanin, beta-carotene, tocopherol (Upasani and Balaraman, 2003; Lu *et al.*, 2006). Spirulina has been shown to improve immune function, reproduction, and has been used with high frequency worldwide as a quality component in broiler chicken feed (Yoshida and Hoshii, 1980) for improving meat quality and egg yolk color (Toyomizu *et al.*, 2001).

The intestinal epithelium acts as a natural barrier against pathogenic bacteria and toxic substances that are present in the intestinal lumen. These stressors cause disorders in the normal microflora and intestinal epithelium that can alter the permeability of this natural barrier, facilitating the invasion of pathogens and harmful substances, altering metabolism, ability to digest and absorb nutrients and leads to the installation of chronic inflammatory processes of intestinal mucosa (Oliveira *et al.*, 1999). Therefore, there is a reduction in villi, decreased digestive activity and absorption of enterocytes. Yoshida and Hoshii (1980) administered Spirulina in different amounts to growing chickens, with satisfactory results at levels from 5 to 10%/kg feed.

The action of probiotics can be explained by some mechanisms such as the production of

antimicrobials, organic acids, involved in protecting the absorbent surfaces of villi and toxins produced by pathogens, and stimulating immunity (Pelicano *et al.*, 2004). On the other hand, prebiotic effects are based on the reduction of many pathogenic or non-pathogenic intestinal bacteria due to decreased pH because of increased lactic acid synthesis in cecum (Choi *et al.*, 1994). Some bacteria can recognize binding sites of molecules on the surface of the mucosa, and intestinal colonization by pathogenic bacteria is thus reduced. Therefore, there is a lower incidence of infectious processes and functions of secretion, digestion and absorption of nutrients that can be properly performed by the mucosa (Iji and Tivey, 1998).

## MATERIALS AND METHODS

The experiment was carried out in a laying hens farm. The objective of the research was focused on the study of the new nutritional supplement – ZooBioR2, as well as on the influence of this remedy on young laying hens. *ZooBioR2* is a complex natural remedy containing biological active compounds derived from the cyanobacterium *Spirulina (Arthrospira) platensis* (SP). *ZooBioR2* (ZBR2) contains amino acids, including free immunoactivity ones and as component parts of peptides and proteins; polysaccharides; sulphated polysaccharides; phospholipids and the trace elements zinc and selenium (Rudic *et al.*, 2004).

The research was carried out in duplicate, for 60 days, each on 70 laying hens of 23 weeks of age from the Braun-Nic hybrid, divided into 5 groups, each of 14 birds. The birds included in the research were analogous in terms of age, physiological condition, origin, body weight, being accommodated in the same hall, with the same environmental conditions, and veterinary care. During the experiment the birds were monitored and assessed for health status. At the same time, the objective of the research was to evaluate the effect of product *ZooBioR2*, administered to birds, on micromorphology of intestinal mucosa. The product *ZooBioR2* was administered in different doses, according to the experimental scheme, from Table 1.

Table 1. Dosage of product *ZooBioR2*

Birds` groups	No of birds	Administration route	Dose, mg active substance/kg of fodder	Administration regimen
Control	14	-	-	
Experimental 1	14		5.0	
Experimental 2	14	per os	10.0	
Experimental 3	14	with food	15.0	daily
Experimental 4	14		20.0	

To assess the state of health, at the beginning of the experiment, and later, the birds were examined clinically. At the end of the experiment the hens were euthanized by cervical dislocation.

Tissue samples from the duodenum, jejunum, ileum and cecum of all experimental treatments and control group were subjected to morphometric analysis, after fixation with formaldehyde 4%, paraffin embedding and staining with hematoxiline-eosine (HE), hematoxiline-eosine-Alcian blue (HEA) and PAS.

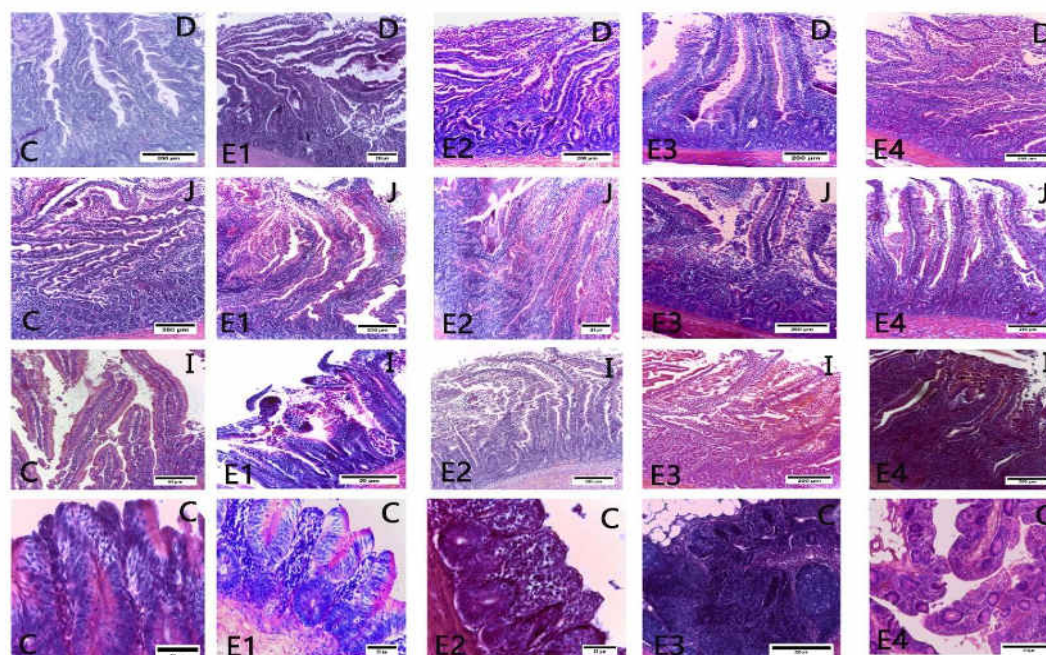
*Statistical Analysis.* The results of morphometry of intestinal mucosa were statistically processed using one way analysis of variance (ANOVA test) to highlight the significant differences between all groups, followed by Fisher's test (test for two samples variances) and Student's t-test to quantify the significant differences between control and each experimental group. All statements of significance were based on  $p < 0.05$ . All data were automatically analyzed by computer using Microsoft Office 2010 software package (Microsoft Inc., USA).

## RESULTS

The general microscopic structure of intestinal mucosa was typical for each section analyzed. A

specific feature of the duodenum was the presence of leaf-shaped villi and straight, longitudinal crypts (Fig. 1 D). In jejunum, the villi are digitiform in appearance and the crypts predominantly longitudinal (Fig. 1 J). In the ileum villi are shorter and their diameter is smaller than in jejunum (Fig. 1 I). The villi of the cecum are short and conical in shape, while the crypts are branched and more superficial compared to other fragments (Fig. 1C). The interior of the villi and the spaces between the crypts are occupied by connective tissue containing numerous blood vessels and cells associated with the immune system - lymphocytes and plasma cells. There were no differences between different examined sections of the same bowel area throughout the experiment. The submucosal tunic and muscular tunic had a typical structure.

The villi of the cecum are short and conical in shape, while the crypts are branched and more superficial compared to other fragments. The interior of the villi and the spaces between the crypts are occupied by connective tissue containing numerous blood vessels and cells associated with the immune system - lymphocytes and plasma cells.



Letters from upper right corner mark the intestinal segment: D= duodenum; J= jejunum; I=ileum; C= cecum. Letters from bottom left corner mark the groups: C= control; E1-E4= experimental

Figure 1. Duodenum C group - A specific feature of the duodenum was the presence of leaf-shaped villi and straight, longitudinal crypts. HEA stain x100; E1. The height of the villi and their diameters is smaller than in control group. HEA stain x100. E2. PAS stain x40. E3. PAS stain x100. E4. HEA stain x100. Jejunum C group. The villi are digitiform in appearance and the crypts predominantly longitudinal. HEA x40. E1. PAS x40. Villi dimensions and height depth diameter are smaller than in duodenum. E2. HEA x100. E3 HEA x100. E4. PAS x100. The villi are digitiform in appearance and the crypts predominantly longitudinal. Muscularis mucosa thickness decreased from an average of 295  $\mu\text{m}$  in the C group to an average of 244  $\mu\text{m}$  in E4 group. Ileum C group. HEA stain x100. E1 PAS x100. E2 HEA x40. E3. PAS x100. E4 PAS x100. Cecum C group HE x400. E1 PAS x400. E2 HEA x400. E3. PAS x100. Agglomerations of lymphoid follicles in the submucosa. E4 PAS x100. Subepithelial and interglandular lymphoid infiltrations.

The synthesized results of the intestinal morphometric analysis are presented in the Table 2. The morphometric parameters that characterize the mucosal architecture varied slightly between the control diet and the one with ZBR2. Differences were found in the length of the villi and the depth of the crypts in the duodenum, jejunum, ileum, and cecum. There were statistically significant differences in fasting between the experimental diet and the control group.

The inclusion in the diet of ZBR2 determined the decrease of the average height of the villi in all intestinal segments, being most significant ( $p = 0.011$ ) in the cecum. The diet with ZBR2 tended to reduce the depth of the crypts, most significant

in duodenum ( $p = 0.065$ ). The ratio between the height of the villi and the depth of the crypt did not show any significant difference. The thickness of the muscular tunic was significantly smaller in the experimental groups, especially in E3 and E4 compared to control, the results being most significant in duodenum ( $p = 0.001$ ) and cecum ( $p = 0.004$ ). Few enterocytes with signs of increased apoptosis were observed in all dietary treatments in the study.

The diameter of the villi decreased significantly in experimental groups (E2-E4) in duodenum, jejunum and most significantly in ileum in E4 group ( $p = 0.008$ ), and not significantly in cecum.

Table 2. Morphometric values of intestinal mucosa during the experiment ( $\mu\text{m}$ )

Intestinal segment	Group	Thickness of musculosa	Crypts depth (Lieberkuhn glands)	Height of villi	Diameter of villi
Duodenum	C	181.2 $\pm$ 32	267.2 $\pm$ 33	1266 $\pm$ 188	338.6 $\pm$ 49
	LE1	172.3 $\pm$ 37	256.4 $\pm$ 36	1161 $\pm$ 194	165.4 $\pm$ 32*
	LE2	154.7 $\pm$ 24	247.8 $\pm$ 28	1050 $\pm$ 162	149.2 $\pm$ 28**
	LE3	143.8 $\pm$ 27*	225.2 $\pm$ 30*	935.8 $\pm$ 113*	142.6 $\pm$ 25**
	LE4	134.6 $\pm$ 24**	194.4 $\pm$ 26**	898.6 $\pm$ 97**	114.2 $\pm$ 18**
Jejunum	C	295.3 $\pm$ 61	292.8 $\pm$ 38	883.4 $\pm$ 83	247.4 $\pm$ 31
	LE1	281.6 $\pm$ 54	254.4 $\pm$ 31	758.2 $\pm$ 82	170.2 $\pm$ 20*
	LE2	270.4 $\pm$ 63	183.6 $\pm$ 24**	812.9 $\pm$ 77	163.6 $\pm$ 22**
	LE3	264.6 $\pm$ 51*	241.8 $\pm$ 32	789.4 $\pm$ 89*	153.9 $\pm$ 19**
	LE4	244.6 $\pm$ 48**	212.4 $\pm$ 27*	730.3 $\pm$ 73**	143.1 $\pm$ 17*
Ileum	C	258.6 $\pm$ 57	200.7 $\pm$ 32	716.8 $\pm$ 62	171.3 $\pm$ 21
	LE1	236.4 $\pm$ 43	182.6 $\pm$ 23	695.6 $\pm$ 68	148.8 $\pm$ 27
	LE2	220.3 $\pm$ 38*	179.4 $\pm$ 26	678.2 $\pm$ 62	130.8 $\pm$ 20
	LE3	224.6 $\pm$ 43	163.8 $\pm$ 28*	640.2 $\pm$ 70*	122.6 $\pm$ 17**
	LE4	204.2 $\pm$ 34**	147.3 $\pm$ 27*	564.6 $\pm$ 62**	110.2 $\pm$ 19**
Cecum	C	368.7 $\pm$ 56	346.5 $\pm$ 48	432.8 $\pm$ 48	233.2 $\pm$ 36
	LE1	255.7 $\pm$ 47	297.6 $\pm$ 52	345.6 $\pm$ 41	219.7 $\pm$ 29
	LE2	215.3 $\pm$ 39	288.5 $\pm$ 38	260.2 $\pm$ 32	234.3 $\pm$ 27
	LE3	184.4 $\pm$ 27*	271.4 $\pm$ 38*	198.4 $\pm$ 28**	221.7 $\pm$ 24
	LE4	107.5 $\pm$ 19**	241.8 $\pm$ 26**	154.4 $\pm$ 18**	211.5 $\pm$ 29

C= control group, LE= experimental groups; \* = significant ( $p < 0.05$ ), \*\* = very significant ( $p < 0.01$ )

## DISCUSSIONS

Toyomizu *et al.* (2001) reported that using *Spirulina platensis* (SP) obtained quite similar results at 40 and 80g/kg in the diet for broilers. Ross and Dominy (1990) and Mariey *et al.* (2012) also reported that birds fed dietary SP had beneficial effects on productivity performance. Intensive birds breeding is accompanied by stress that has a negative impact on animal immunity and performance. The high metabolic rate during intensive feeding is accompanied by an increase in free radical production and any imbalance between synthesis and safe elimination culminates in oxidative stress, which can damage cells and tissues (Miller *et al.*, 1993). Therefore, under conditions of oxidative stress, there is an increased demand for antioxidants to reduce the harmful effects of free radicals on the immune system. Interestingly, feeding with natural, rather than synthetic, antioxidants could be beneficial to animal welfare and consumer safety. Blue-green algae *Spirulina platensis* have been considered a suitable natural antioxidant and immunostimulant product for humans and animals with fewer side effects and more cost-effectiveness than synthetic products (Belay *et al.*, 2002; Khan *et al.*, 2005).

SP is a suitable alternative protein source in diets for raising chickens at a substitution level of 50% of soy. However, the baseline level of amino acids (AA) in the supplementation applied in the control group diet was not sufficient in the SP diet either to create biological responses comparable to the control diet. This observation indicated that a supplement with amino acids required for an improved growth response was reconsidered when diets were replaced by 50% soy. Consequently, a significant improvement in zootechnical data was observed when AA supplementation was extended (AA +SP + diet) according to the currently assumed IAAR (Wecke and Leiber, 2013).

Morphometric measurements of the length of the villi and the depth of the intestine crypts are widely used as one of the factors that contribute to the maintenance of intestinal homeostasis (Franco *et al.*, 2006). The length of the villi is an important factor that determines the absorption surface of the intestine and consequently the efficiency of nutrient absorption (Caspary, 1992). In addition, the villi-crypt ratio is correlated as responding to the cycle of exfoliation and regeneration of the intestinal

epithelium. To date, the effect of microalgae on intestinal morphology has not been studied in birds in our country. However, experiments dealing with the influence of algae on intestinal morphology did not yield equivocal results. Reilly *et al.* (2008) supplemented the piglet diet with *Laminaria digitata* in the diet and obtained significantly shorter villi in the duodenum and jejunum compared to the control group. This result is inconsistent with the observations of Furbeyre *et al.* (2017), who found an increase in the length of the villi and the depth of the crypts in the jejunal and ileal tissues when SP and *Chlorella vulgaris* were applied in piglet diets.

SP did not have a significant effect on the length of the villi and the depth of the duodenal crypts in chickens. However, in the section both parameters decreased significantly. It should be considered that digestion takes place in birds in the upper part of the small intestine respectively in the duodenum and the nutrients released are absorbed mainly in the lower part of the small intestine. Consequently, most nutrient uptake occurs in the jejunum and ileum (Tasaki and Takahashi, 1966) which could be affected when both values namely the length of the villi and the depth of the crypts are reduced. In addition, the shallower depth of the crypts is an indicator for the rate of renewal of epithelial tissue. Both support the hypothesis that an adverse effect on intestinal homeostasis could be created. However, this conclusion is hypothetical and cannot be supported by the growth response observed with the SP diet, which was much higher depending on the AA deficiencies, created by the baseline level of AA supplementation. Moreover, a relationship between the type of diet and the thickness of the muscular tunic was observed in the intestines of birds. The basic level of additional AA in diets with SP led to a significant decrease in the thickness of the muscular tunic in the duodenum and jejunum. An atrophy of the tunic layer of the small intestine may indicate a lower motility of the intestine (Couraud *et al.*, 2006).

This observation was surprising but needs more attention and validation in nutritional studies before such a source effect in chick diets can be mentioned. Lower bowel motility could also be considered a factor that provides more time for digestion and absorption processes. The results in birds with AA supplements support the

conclusion that an alternative protein-related adverse effect on the digestive potential and absorption of the small intestine in growing chickens is unlikely (Velten *et al.*, 2018). Finally, histological evaluation of all representative specimens of organ tissue provided no or only rare or slight nonspecific changes.

Therefore, it is important to emphasize that notable differences in overall health were not observed between control and experimental groups. Consequently, the alternating protein meals of ZBR2 included in the study ratio did not affect the health of the laying hens.

## CONCLUSIONS

Inclusion in the diet of ZBR2, *Spirulina platensis* extract determined a decrease of height of intestinal villi and decreased the depth of the crypts in all intestinal segments. A decrease of crypts depth is an indicator of a higher rate of turn-over of epithelial tissue and could be involved in a better digestibility of the fodder. The thickness of muscular layer of duodenum and cecum was significantly smaller in the experimental group than in control, being also involved in a better digestibility of the fodder.

## REFERENCES

- BELAY, A.; BELAY, A.; BELAY-TEDLA, A. The potential application of spirulina (Arthrospira) as a nutritional and therapeutic supplement in health management. *J. Am. Nutraceutical Assoc.*, v.5, p.27-48, 2002.
- BLINKOVA, L.P.; GOROBETS, O.B.; BATURO, A.P. Biological activity of spirulina. *Zh. Mikrobiol. Epidemiol. Immunobiol.*, v.65, p.114-118, 2001.
- CASPARY, W.F. Physiology and pathophysiology of intestinal absorption. *Am. J. Clin. Nutr.*, v.55, Suppl.1, p.299s-308s, 1992.
- CHOI, K.H.; NAMKUNG, H.; PAIK, I.K. Effects of dietary fructooligosaccharides on suppression of intestinal colonization of *Salmonella typhimurium* in broiler chickens. *Korean J. Anim. Sci.*, v.36, p.71-284, 1994.
- COURAUD, L.; JERMYN, K.; YAM, P.S. *et al.* Intestinal pseudo-obstruction, lymphocytic leiomyositis and atrophy of the muscularis externa in a dog. *Vet. Rec.*, v.159, p.86-87, 2006.

- COWAN, M.M. Plant products as antimicrobial agents. *Clin. Microbiol. Rev.*, v.12, p.564-582, 1999.
- DRAGLAND, S.H.; SENOO, K.; WAKE, K. *et al.* Several culinary and medicinal herbs are important sources of dietary antioxidants. *J. Nutr.*, v.133, p.1286-1290, 2003.
- FRANCO, J.R.G.; MURAKAMI, A.E.; NATALI, M.R.M. *et al.* Influence of delayed placement and dietary lysine levels on small intestine morphometrics and performance of broilers. *Braz. J. Poult. Sci.*, v.8, p.233-241, 2006.
- FURBEYRE, H.; VAN MILGEN, J.; MENER, T. *et al.* Effects of dietary supplementation with freshwater microalgae on growth performance, nutrient digestibility and gut health in weaned piglets. *Animal*, v.11, p.183-192, 2017.
- IJI, P.A.; TIVEY, D.R. Natural and synthetic oligosaccharides in broiler chicken diets. *World's Poult. Sci. J.*, v.54, p.129-143, 1998.
- KHAN, Z.; BHADOURIA, P.; BISEN, P.S. Nutritional and therapeutic potential of spirulina. *Curr. Pharm. Biotechnol.*, v.6, p.373-379, 2005.
- KUHAD, A.; TIRKEY, N.; PILKHWAL, S.; CHOPRA, K. Renoprotective effect of Spirulina fusiformis on cisplatin-induced oxidative stress and renal dysfunction in rats. *Renal Fail.*, v.28, p.247-254, 2006.
- LU, H.K.; HSIEH, C.C.; HSU, J.J. *et al.* Preventive effects of Spirulina platensis on skeletal muscle damage under exercise-induced oxidative stress. *Eur. J. Appl. Physiol.*, v.98, p.220-226, 2006.
- MARIEY, Y.A.; SAMAK, H.R.; IBRAHEM, M.A. Effect of using spirulina platensis algae as a feed additive for poultry diets: 1- productive and reproductive performances of local laying hens. *Egypt. Poult. Sci.*, v.32, p.201-215, 2012.
- MILLER, J.K.; BRZEZINSKA-SLEBODZINSKA, E.; MADSEN, F.C. Oxidative stress, antioxidants, and animal function. *J. Dairy Sci.*, v.76, p.2812-2823, 1993.
- OLIVEIRA, M.D.; MONTEIRO, M.; ROBBS, P.; LEITE, S.G.F. Growth and chemical composition of spirulina maxima and spirulina platensis biomass at different temperatures. *Aquac. Int.*, v.7, p.261-275, 1999.
- PELICANO, E.R.L.; SOUZA, P.A.; SOUZA, H.B.A. *et al.* Productive traits of broiler chicken fed diets containing different growth promoters. *Braz. J. Poult. Sci.*, v.6, p.177-182, 2004.
- REILLY, P.; O'DOHERTY, J.V.; PIERCE, K.M. *et al.* The effects of seaweed extract inclusion on gut morphology, selected intestinal microbiota, nutrient digestibility, volatile fatty acid concentrations and the immune status of the weaned pig. *Animal*, v.2, p.1465-1473, 2008.
- ROSS, E.; DOMINY, W. The nutritional value of dehydrated blue-green algae (Spirulina platensis) for poultry. *Poult. Sci.*, v.69, p.794-800, 1990.
- RUDIC, V.; GUDUMAC, V.; DIUG, E. *et al.* Technology of obtaining the product BioR and studies of its immunomodulatory action, in vitro" (in Romanian). Scientific Yearbook of State University of Medicine and Pharmacy "N. Testemițanu" 5.ed. Chișinău; [s.n.], 2004, p.138-144
- TASAKI, I.; TAKAHASHI, N. Absorption of amino acids from the small intestine of the domestic fowl. *J. Nutr.*, v.88, p.359-364, 1966.
- TOYOMIZU, M.; SATO, K.; TARODA, H. *et al.* Effects of dietary spirulina on meat colour in muscle of broiler chickens. *Br. Poult. Sci.*, v.42, p.197-202, 2001.
- UPASANI, C.D.; BALARAMAN, R. Protective effect of spirulina on lead induced deleterious changes in the lipid peroxidation and endogenous antioxidants in rats. *Phytother. Res.*, v.17, p.330-334, 2003.
- VELTEN, S.; NEUMANN, C.; SCHÄFER, J.; LIEBERT, F. Effects of the partial replacement of soybean meal by insect or algae meal in chicken diets with graded amino acid supply on parameters of gut microbiology and dietary protein quality. *Open J. Anim. Sci.*, v.8, p.259-279, 2018.
- WECKE, C.; LIEBERT, F. Improving the reliability of optimal in-feed amino acid ratios based on individual amino acid efficiency data from N balance studies in growing chicken. *Animals*, v.3, p.558-573, 2013.
- YOSHIDA, M.; HOSHII, H. Nutritive value of spirulina, green algae, for poultry feed. *Jpn Poult. Sci.*, v.17, p.27-30, 1980.